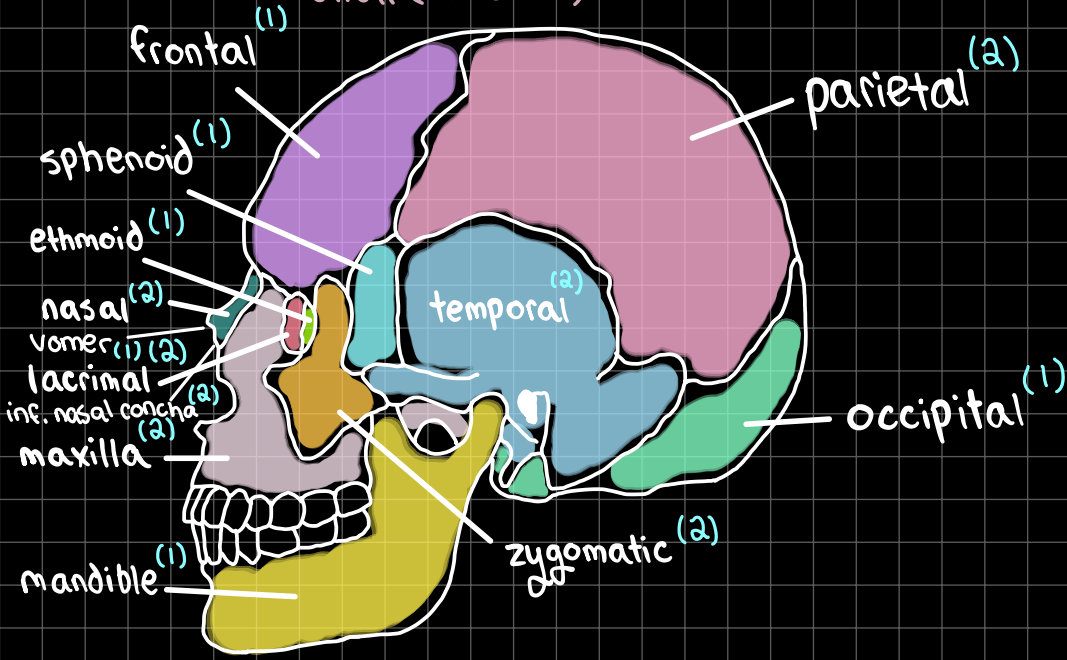
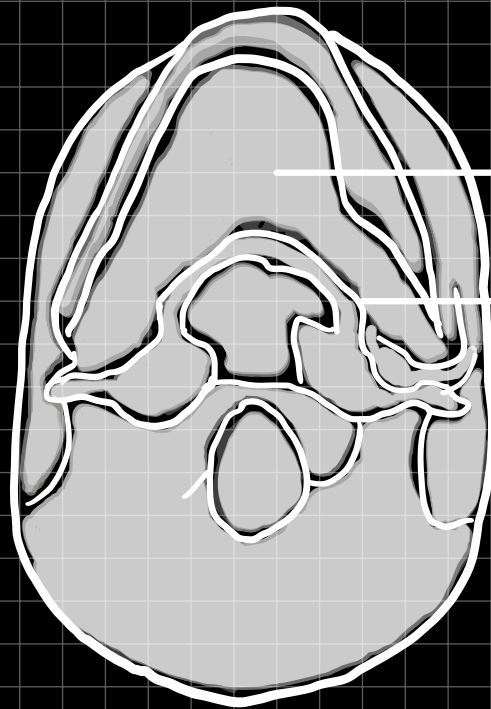
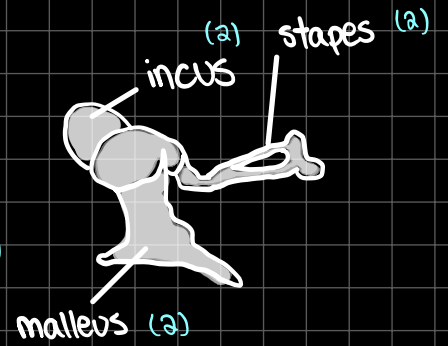


BONES

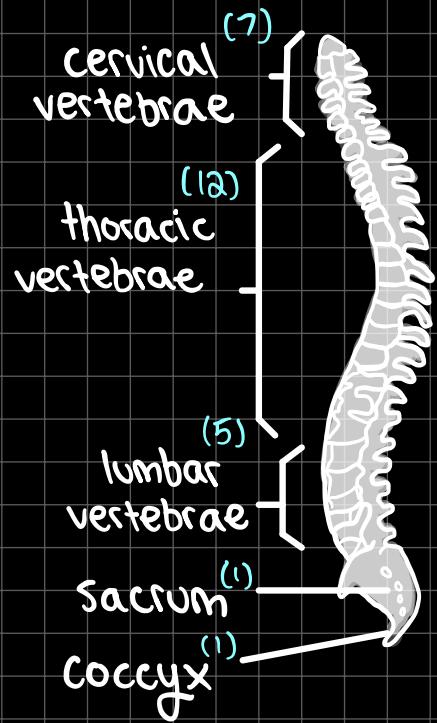
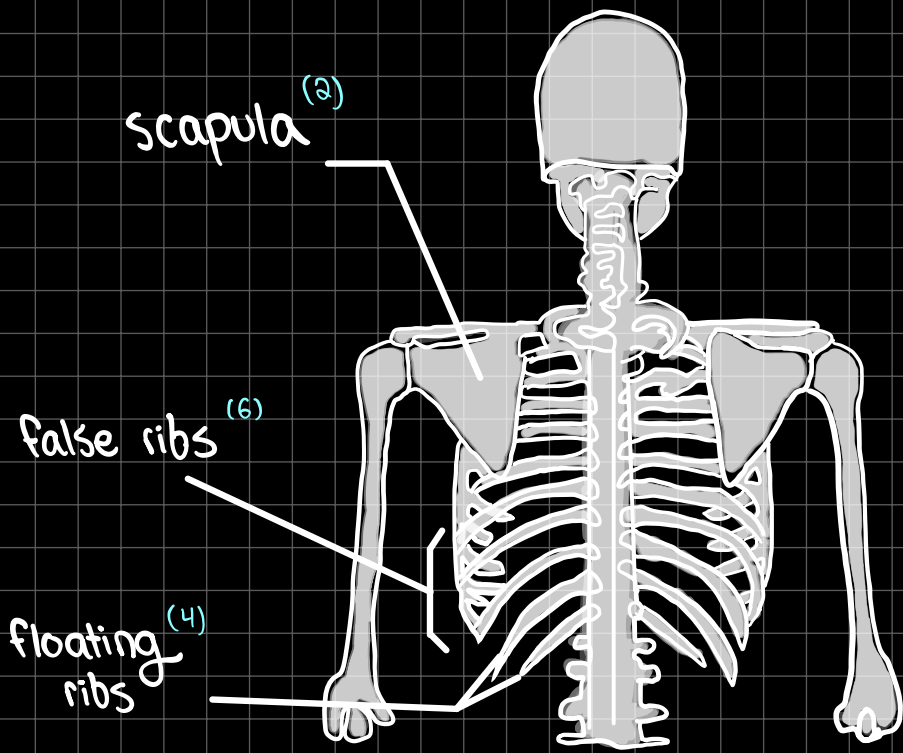
Skull (lateral)



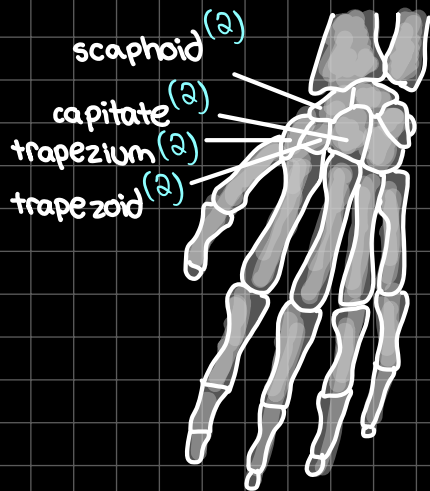
right ear (lateral)



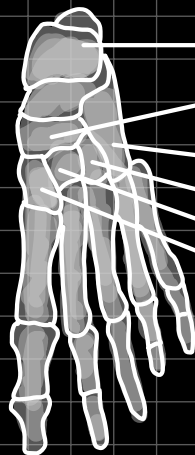
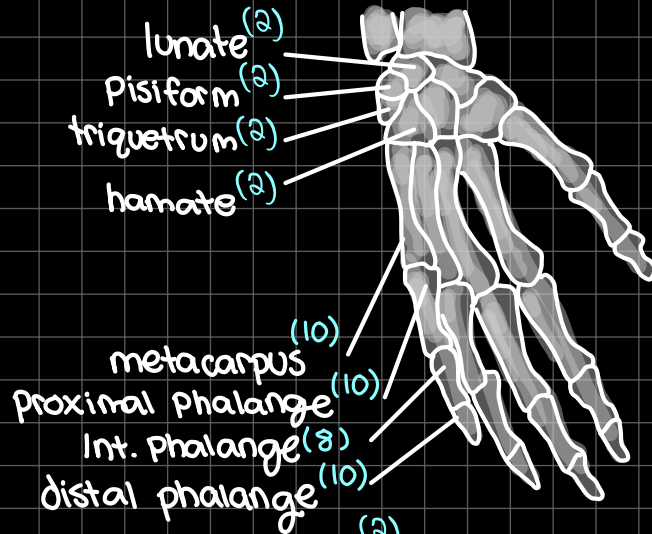
Skull (inferior)



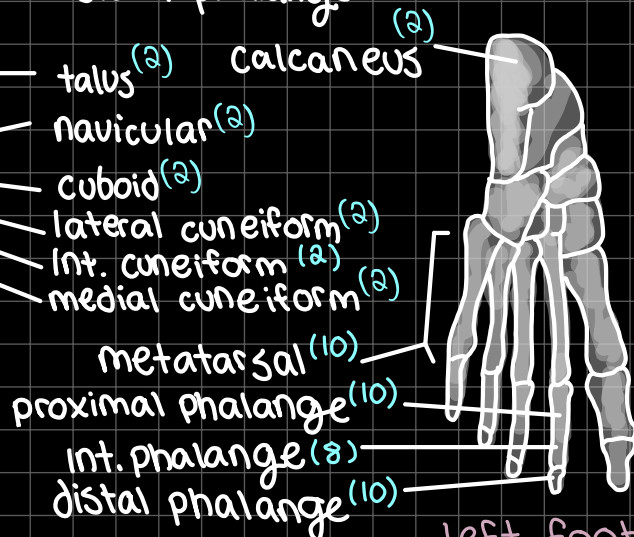
left hand (dorsal)



left hand (palmar)



left foot (superior)



left foot (inferior)

